

Case report

Open Access

## Primary psoas abscess due to *Streptococcus milleri*

Nitin B Bagul\*<sup>1</sup>, Abeywardana MS Abeysekara<sup>2</sup> and Sabu Jacob<sup>2</sup>

Address: <sup>1</sup>Department of Surgery, University Hospital of North Tees, Stockton, UK and <sup>2</sup>Department of Surgery, King George Hospital, Goodmayes, Essex, UK

Email: Nitin B Bagul\* - drnitinbb@gmail.com; Abeywardana MS Abeysekara - abey@hotmail.co.uk; Sabu Jacob - sabu.jacob@bhrhospitals.nhs.uk

\* Corresponding author

Published: 26 February 2008

Received: 9 December 2007

*Annals of Clinical Microbiology and Antimicrobials* 2008, **7**:7 doi:10.1186/1476-0711-7-7

Accepted: 26 February 2008

This article is available from: <http://www.ann-clinmicrob.com/content/7/1/7>

© 2008 Bagul et al; licensee BioMed Central Ltd.

This is an Open Access article distributed under the terms of the Creative Commons Attribution License (<http://creativecommons.org/licenses/by/2.0>), which permits unrestricted use, distribution, and reproduction in any medium, provided the original work is properly cited.

### Abstract

Primary Psoas abscess (PPA) is an infrequent clinical entity with obscure pathogenesis and vague clinical presentation. High index of clinical suspicion is required for the diagnosis of psoas abscess. We also emphasises the importance of bacteriological confirmation of microorganism involved, although *Staphylococcus aureus* remains the commonest pathogen. We report an extremely rare case of PPA caused by *Streptococcus milleri*. Only one case has been reported in literature so far.


### Introduction

Primary psoas abscess (PPA) is extremely rare clinical entity, which potentially carries high mortality and morbidity if diagnosis is delayed. A PPA has no obvious focus of infection, with the commonest pathogen being *Staphylococcus aureus* (SA). We report an extremely rare case of PPA caused by *Streptococcus milleri* (SM). Only one case has been reported in literature as far as our knowledge [1]. It carries a good prognosis provided early drainage is performed and parenteral antibiotic therapy is administered to patient. High index of clinical suspicion is required for the diagnosis of psoas abscess (PA). We also emphasises the importance of bacteriological confirmation of microorganism involved.

### Illustrative case history

A 57-year-old man was admitted to hospital with seven-day history of right upper quadrant and loin pain radiating to right leg and umbilicus. Patient also complained of fever, chills, general malaise, decreased appetite. Patient denied any urinary symptoms. Patient had significant past medical history of coronary artery bypass surgery 5 years ago and laparoscopic cholecystectomy 2 years ago. On

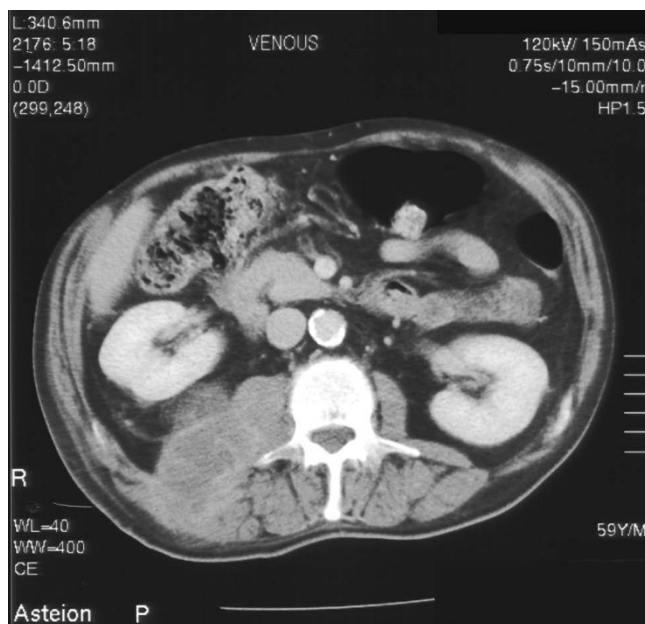
general examination he was pale, temp-37.5 degree Celsius. On physical examination he had fullness in right flank, which was tender and fluctuant. Laboratory investigation revealed leucocytosis of  $14.9 \times 10^9/l$ . Plain abdominal radiograph showed a soft tissue shadow on right upper quadrant. Ultrasonography (USS) guided aspiration was undertaken and 250 ml of thick brown blood stained pus was drained and sent for microscopy and culture. Drain was kept in situ. Microbiology reported SM as causative organism sensitive to penicillin and erythromycin. Patient was started on intravenous 1.8 g qds benzyl penicillin for 4 weeks. Computed Tomography (CT) and barium enema was performed to rule out bowel origin (Figure 1 & 2). Magnetic resonance imaging scan was performed which showed abscess in posterior abdominal wall extending to retro peritoneum abutting the right kidney. Drain was removed in 20 days after ultrasound confirmation. The patient's general condition improved over a period of 28 days during the stay in hospital. Patient was subsequently discharge and on follow up of one year he is doing fine.



**Figure 1**  
**Computed tomogram of abdomen showing right psoas abscess abutting the right kidney.**

## Discussion

Mynter first described psoas abscess in 1881 referring to it as psoitis [2]. PA is a relatively uncommon condition in western countries. PA may be classified as primary or secondary, depending on the presence or absence of underlying



**Figure 2**  
**Computed tomogram of abdomen showing right psoas abscess extending from above the right kidney.**

ing infection. PPA occurs probably as a result of haematogenous spread of an infectious process from an occult source in the body. Incidence of PA was 12 cases per year worldwide in 1992 [3]. This was a significant increase from the calculated occurrence of 3.9 cases per year before 1985 [4]. The increase was attributed to improved diagnosis with the widespread use of computed tomography. PPA is most prevalent in young patients and occurs rarely in the elderly population. Certain groups of immunocompromised patients, such as diabetics, the elderly, patients on steroids, patients with malignancies, and alcoholics, usually present with infrequent sites of infection. SA is the causative organism in over 88% of patients with PPA [4], *Streptococcus species* 4.9% and *Escherichia coli* 2.8%. Other rare pathogens reported are *Mycobacterium tuberculosis*, *Streptococcus species*, *Escherichia coli*, *Salmonella enteritidis*, *Pneumococcal*, *Pseudomonas aeruginosa*, *Proteus Mirabilis*, *Yersinia enterocolitica*, *Bacteroides*, *Pasteurella multocida*, *Klebsiella*, *Serratia marcescens* *Mycobacterium kansasii*, and *Mycobacterium xenopi*. Methicillin resistant *Staphylococcus aureus* is also known pathogen [5].

SM is very rare organism to cause PA. It is Gram positive coccus which is usually involved in endocarditis, peritonitis, intracranial abscess, intraspinal abscess, liver abscess and lung abscess [6]. It belongs to *Streptococcus milleri* group along with *Streptococcus intermedius* and *anginosus*.

The classical symptoms of patients with PPA are fever, flank or abdominal pain, and limp. The patient mentioned in our case report presented with similar symptoms. Other symptoms may include malaise, weight loss, or presentation with a mass. Physical findings, such as external rotation of the ipsilateral hip, flank tenderness, and fullness of the flank may be seen. Laboratory tests may reveal raised white cell count, anaemia, and elevated erythrocyte sedimentation rate, and bacteriological confirmation of microorganism is utmost importance.

Radiographic imaging studies help in diagnosis and may also help in finding an underlying cause. Plain abdominal x-ray may reveal an abnormal psoas shadow or a soft tissue mass. USS of the abdomen may demonstrate a hypochoic mass suggestive of PA, but cannot identify the cause of the abscess. CT scan of the abdomen with contrast is the most efficient and accurate imaging study in diagnosing a PA. CT scanning is now used as the first line of investigation. CT scan of the abdomen not only helps in diagnosis, but also in identification of the etiology, for therapeutic purposes, and postoperative follow-up [7,8].

An adequate knowledge of the causative organisms should guide the initial choice of antibiotics. But at the same time the importance of bacteriological confirmation of microorganism involved should not be ignored. It has

been suggested that in PPA, antistaphylococcal antibiotic therapy should be started before final bacteriologic diagnosis [4]. However, the identification of non-staphylococcus organisms in some patients with PPA and the identification of staphylococcus in patients with secondary PA, makes it prudent in all cases of psoas abscess to start treatment with broad spectrum antibiotics like cephalosporins, quinolones, imipenem and clindamycin pending final bacteriologic diagnosis [9]. Antibiotics are sometimes continued up to four to six weeks after complete drainage of the abscess.

Drainage can be surgical or radiologically. Percutaneous drainage may be difficult in some patients because of the location of the abscess, but whenever possible it should be employed. Even in patients with complex, multiloculated abscesses, percutaneous drainage should be attempted and open surgical drainage should be reserved if percutaneous drainage fails. Patients with secondary psoas abscess require correction of their underlying disease in addition to the drainage procedure. Extraperitoneal drainage is a safe, effective method of draining these abscesses. Compared to percutaneous drainage, an advantage with open drainage is that debridement of adjacent tissues can be done, which may help in shortening recovery time [10]. The prognosis of PPA is better compared to secondary abscess [4].

### Conclusion

High index of clinical suspicion is required for the diagnosis of psoas abscess. We also emphasises the importance of bacteriological confirmation of microorganism involved, although *Staphylococcus aureus* remains the commonest pathogen.

### Competing interests

The author(s) declare that they have no competing interests.

### Authors' contributions

All authors were involved in the care of the patient. NBB drafted the manuscript. AMSA, SJ critically reviewed and improved the manuscript. All authors read and approved the final manuscript.

### Consent

Written informed consent was obtained from the patient for participation in this research.

A copy of the written consent is available for review by the Editor-in-Chief of this journal.

### References

1. Ibanez Perez de la Blanca MA, Mediavilla Garcia JD, Martinez R, Mohamed-Balghata MO, Arrebola Nacle JP, Jimenez-Alonso J: **Primary**

**abscess of the psoas muscle caused by Streptococcus milleri.** *Clin Infect Dis* 1992, **15(5)**:883-4.

2. Mynter H: **Acute psoitis.** *Buffalo Med Surg J* 1881, **21**:202-210.
3. Taiwo B: **Psoas abscess: A primer for the internist: Case Report.** *South Med J* 2001, **94**:78-80.
4. Gruenwald I, Abrahamson J, Cohen O: **Psoas abscess: case report and review of the literature.** *J Urol* 1992, **147**:1624-1626.
5. Walsh TR, Reilly JR, Hanley E, Webster M, Peitzman A, Steed DL: **Changing etiology of iliopsoas abscess.** *Am J Surg* 1992, **163**:413-416.
6. Ruoff KL: **Streptococcus anginosus ("Streptococcus milleri"): the unrecognized pathogen.** *Clin Microbiol Rev* 1988, **1(1)**:102-108.
7. Cantasdemir M, Kara B, Cebi D, Selcuk ND, Numan F: **Computed tomography-guided percutaneous catheter drainage of primary and secondary iliopsoas abscesses.** *Clin Radiol* 2003, **58(10)**:811-5.
8. Melissas J, Romanos J, de Bree E, Schoretanitis G, Askoxylakis J, Tsiftsis DD: **Primary psoas abscess. Report of three cases.** *Acta Chir Belg* 2002, **102(2)**:114-7.
9. Santaella RO, Fishman EK, Lipsett PA: **Primary vs secondary iliopsoas abscess. Presentation, microbiology, and treatment.** *Arch Surg* 1995, **130(12)**:1309-13.
10. Garner JP, Meiring PD, Ravi K, Gupta R: **Psoas abscess – not as rare as we think?** *Colorectal Dis* 2007, **9(3)**:269-74.

Publish with **BioMed Central** and every scientist can read your work free of charge

"BioMed Central will be the most significant development for disseminating the results of biomedical research in our lifetime."

Sir Paul Nurse, Cancer Research UK

Your research papers will be:

- available free of charge to the entire biomedical community
- peer reviewed and published immediately upon acceptance
- cited in PubMed and archived on PubMed Central
- yours — you keep the copyright

Submit your manuscript here:  
[http://www.biomedcentral.com/info/publishing\\_adv.asp](http://www.biomedcentral.com/info/publishing_adv.asp)

